

Editorial

Open Access



What role does hand-assistance have in minimally invasive pancreatic surgery?

Greta Donisi^{1,2}, Alessandro Zerbi^{1,2}

¹Pancreatic Surgery Unit, IRCCS Humanitas Research Hospital, Milan 20089, Italy.

²Department of Biomedical Sciences, Humanitas University, Milan 20090, Italy.

Correspondence to: Dr. Greta Donisi, Pancreatic Surgery Unit, IRCCS Humanitas Research Hospital, via Manzoni 56, Rozzano, Milan 20089, Italy. E-mail: Greta.donisi@humanitas.it

How to cite this article: Donisi G, Zerbi A. What role does hand-assistance have in minimally invasive pancreatic surgery? *Mini-invasive Surg* 2021;5:38. <https://dx.doi.org/10.20517/2574-1225.2021.55>

Received: 25 Apr 2021 **First Decision:** 4 Jun 2021 **Revised:** 11 Jun 2021 **Accepted:** 27 Jul 2021 **First online:** 3 Aug 2021

Academic Editors: Andrew A. Gumbs, Kit Fai LEE, Giulio Belli **Copy Editor:** Yue-Yue Zhang **Production Editor:** Yue-Yue Zhang

MINIMALLY INVASIVE SURGERY: RATIONALE, ADVANTAGES AND LIMITATIONS

Surgery poses an important stress on the patient from both physical and psychological points of view *per se*. It has become clearer with time that, regardless of the type of surgical operation, a smaller surgical incision could reduce the operation-induced stress. With advancements in technology, great efforts have been made in trying to reduce this burden on the patient, leading to the development of minimally invasive surgery (MIS)^[1,2]. MIS has gained increasing support since its introduction and has undergone continuous improvements and evolutions to the point of becoming, nowadays, the standard of care for many surgical procedures such as cholecystectomy, adrenalectomy, splenectomy, and fundoplication. MIS encompasses several different approaches which have in common the aim of decreasing the impact of the surgical operation on the patient. The first approach to be developed and widely accepted in clinical practice was laparoscopy. Among the well-established advantages of laparoscopic surgery, we have decreased pain, shorter length of stay, faster postoperative recovery, and a better visualization of secluded anatomical spaces which would otherwise require a large incision to be correctly exposed^[3]. All of this comes at the price of decreased dexterity, diminished tactile feedback, and inherent limitations posed by restricted degrees of freedom of laparoscopic instrumentation, which may result in a longer operative time compared to the open approach for complex surgical procedures^[4]. In recent years, an alternative to the laparoscopic technique has been proposed with the introduction of robotic platforms in surgery. Potential advantages of robotic surgery are filtration of tremors, better dexterity, higher degrees of freedom with the EndoWrist system, and better



© The Author(s) 2021. **Open Access** This article is licensed under a Creative Commons Attribution 4.0 International License (<https://creativecommons.org/licenses/by/4.0/>), which permits unrestricted use, sharing, adaptation, distribution and reproduction in any medium or format, for any purpose, even commercially, as long as you give appropriate credit to the original author(s) and the source, provide a link to the Creative Commons license, and indicate if changes were made.



operative field visualization with 3D imaging. Nonetheless these advantages have to be balanced with drawbacks such as lack of haptics and high cost in terms of both initial investment in purchasing the robotic platform and single operation cost.

MIS IN THE PANCREATIC SURGERY FIELD: A STEEP PATH

Despite all the hype around these new technologies, the implementation and diffusion of MIS have been hampered by the large amount of time and dedication necessary to master the techniques to have results comparable to the open approach. The concept of learning curve became particularly popular with the advent of minimally invasive surgery, when surgeons needed to completely rethink their abilities and adapt them to new techniques and technologies. It has also been postulated that the learning curve appears to be longer in MIS relative to open surgery, and that the curve becomes steeper and steeper with the increasing complexity of surgical procedures^[5]. For complex major abdominal surgeries, a great number of procedures is required to master the technique, and there may be dangerously high morbidity and mortality rates at the beginning of the learning curve. This has been particularly the case of pancreatic surgery.

Despite the appeal of MIS and its widespread adoption in several fields of surgery, the attitude of pancreatic surgeons has been initially tepid. On the one hand, there was the conceptual problem of whether in complex and demanding surgical operations such as pancreatic resections the size of the incision can truly be considered the main contributor to surgical trauma. On the other hand, some peculiar aspects of pancreatic surgery have initially hampered the widespread diffusion of the minimally invasive approach in this field: the peculiar retroperitoneal location of the pancreas, its delicate texture and proximity to major vessels, the complexity of the dissection, the concerns regarding oncological safety in the case of malignancy, the difficulty of the anastomotic components, and the still relatively high morbidity and mortality that characterize pancreatic resections^[6-10]. Another more practical matter is the relative rarity of pancreatic diseases and the complexity of most cases, which make them not suitable to be approached minimally invasively by surgeons at the beginning of their learning curve; the result is an even longer time to reach proficiency and an acceptable morbidity and mortality rate^[11].

Reports of the initial experience with totally laparoscopic pancreatic surgery showed no apparent advantage for pancreaticoduodenectomy, with no improvement in postoperative outcomes and increased morbidity. Conversely, the results are promising for distal pancreatectomy, since it was associated with acceptable operative time and reduced morbidity and length of stay (LOS)^[12].

HAND-ASSISTED LAPAROSCOPIC SURGERY

Rationale and limitations

To overcome the difficulties in adaptation of complex procedures from an open approach, some hybrid techniques have been developed for laparoscopy.

One of the proposed approaches is hand-assisted laparoscopic surgery (HALS): a mini-laparotomy is planned through which the surgeon can insert his or her hand covered by a glove or a hand port that prevents the loss of the pneumoperitoneum. This allows for the surgical operation to be performed via laparoscopy but with the help of an intra-abdominal hand. At the beginning, this technique was greeted with skepticism because of the need to perform a laparotomic incision, which is in direct contrast with the principle of minimal invasivity and because of the lack of adequate instruments able to maintain the pneumoperitoneum with an intra-abdominally inserted hand^[13]. However, with the development of appropriate instruments, HALS found its niche in enabling the surgeon to start approaching major abdominal operations in laparoscopy, with as safety net the familiarity and the expertise of having a hand

directly in contact with the structures. Clear pros of this approach are restoration of the tactile feedback and better manipulation of tissues, such as better organ retraction, finger blunt dissection, exposure and control of possible unexpected intraoperative bleeding and complications^[14,15], and a shorter operative time than laparoscopy^[16], while maintaining some of the advantages of MIS over the open approach, notably a lower estimated blood loss and a shorter LOS. Among the cons, there is clearly the additional surgical trauma posed by the mini-laparotomy, although this problem may be partially mitigated by using this technique in operations which would already require an incision to retrieve the resected specimen. Moreover, despite the handiness of having a direct access to the abdominal cavity, the presence of the hand may reduce the space and range of movements of laparoscopic instrumentation and impair vision^[13].

Fields of use

After its introduction, this technique was initially adopted in several different fields of surgery, in which a pure laparoscopic approach was still striving to be undertaken. In esophagogastric surgery, HALS was applied to both trans-hiatal esophagectomy and total and partial gastrectomy with good results in terms of postoperative and oncological outcomes^[17-19]. A trial was also made in bariatric surgery, but no advantages were found over the open approach for gastric bypass in terms of incidence of incisional hernia and reduction of LOS despite an increased cost^[20]. One of the areas in which HALS has had greater success is colorectal surgery in which an incision is needed anyway, no matter the approach, to extract the specimen and possibly perform the anastomosis. HALS has been used for partial or total colectomy, anterior rectum resection, and abdominoperineal resection, and it maintains the advantages of laparoscopy in terms of bowel movements, refeeding, and hospital stay^[21-24]. Another application of HALS was in the living-donor nephrectomy, where it showed a shorter warm ischemic time than pure laparoscopy, while offering a smaller incision and faster recovery than the open approach^[25-28]. From initial reports, HALS appeared to facilitate the laparoscopic approach, increasing the level of subjective safety and thus shortening the learning curve.

HALS in the pancreatic surgery field

In pancreatic surgery, preliminary data were presented by Cuschieri^[29] and Gagner and Gentileschi^[30], in the early era of pancreatic laparoscopy, presenting the advantages of the hand-assisted technique over the totally laparoscopic approach for such major procedures in terms of safety, exposure, and oncological appropriateness. Furthermore, HALS can provide particular advantages in the case of malignancy, allowing for palpation of the tumor and manual staging, and in the case of voluminous cystic lesions, which can be more effectively removed en-bloc^[31-35].

The hand-assisted pancreatic resections were performed with the insertion of trocars along with a subcostal mini-laparotomy, through which the non-dominant hand was inserted to provide traction and direct palpation, while the demolition and reconstruction phase were both accomplished via laparoscopic instrumentation by the dominant hand. In the case of Pancreaticoduodenectomy (PD), all three anastomosis were performed intracorporeally^[30], which is also because mini-laparotomy is usually located in a position not favorable to be exploited for an open pancreatic anastomosis^[36].

The HALS approach was mostly used to perform Distal Pancreatectomy (DP) because it is a relatively easier procedure without need for complex anastomosis and therefore a greater effort has been put in trying to make this procedure as less invasive as possible. Initial experience with totally laparoscopic DP has been encouraging, stating a marked reduction of LOS, but, at the same time, relevant limitations were identified, such as a long operative time and a high conversion rate^[37,38]. At the beginning, trying to transition from a purely open approach to a totally minimally-invasive procedure, HALS appeared to be a good compromise, and several reports have been published stating its advantages^[39,40]. Postlewait *et al.*^[41] reported a lower

intraoperative blood loss and shorter hospital stay than open surgery and comparable perioperative and oncological outcomes. Gamboa *et al.*^[16] showed similar results and additionally reported a shorter operative time than totally minimally invasive approach, a similar LOS, and a lower conversion rate, even though patients undergoing hand-assisted distal pancreatectomy (HADP) had more comorbidities and a higher number of previous abdominal operations. Kneuert *et al.*^[42] reported the outcomes of laparoscopic DP (LDP) at their institution over an 11-year period; a reduced use of hand-assistance was observed with growing experience and a reduced LOS in TLS relative to HALS. A similar trend in reduction of HALS use over time was reported by Jayaraman *et al.*^[43] and Nakamura *et al.*^[44]. A relevant piece of literature includes HADP in the laparoscopic cases, and it is therefore difficult to extrapolate data on specific HADP outcomes^[45-52]. The current available literature on the topic is summarized in [Table 1](#); articles where the surgical technique is not specified were excluded. Placement of trocars and hand-port is shown in [Figure 1](#).

Some reports have postulated a non-inferiority of the hand-assisted approach for PD relative to open, but its usefulness has been questioned^[29,30,62-64]. In PD, the advantage of hand assistance does not appear to be striking. This is probably ascribable to the fact that the complex reconstruction phase, in HADP, is performed intracorporeally, and, if a surgeon has enough laparoscopic skills to perform the reconstructive part, he conceptually should not need the help of the hand in the demolition phase^[36]. Accordingly, recent literature reports a very limited adoption (0.6%) of the hand-assisted approach for PD^[36]. Some hybrid approaches have been proposed, with the demolition phase performed with a hand-assisted approach and the reconstruction phase with an open approach via a mini-laparotomy^[65].

LAPAROSCOPIC-ASSISTED SURGERY

A similar but somewhat different hybrid approach that appeared to be more suitable for PD is laparoscopic-assisted surgery (LAS). In LAS, the preparation and part of the demolition phase of the surgical operation is managed via laparoscopy, while the reconstruction part is performed out of the body via a small laparotomic incision^[66]. With this approach, we are able to take advantage of the improved vision of secluded spaces given by the laparoscopy, sparing a large incision to the patient and granting a faster postoperative recovery, while assuring an adequate anastomosis technique and hemostasis through a small incision that can also be used for the retrieval of the resected specimen^[67,68]. Several authors, in the initial phase of approaching minimally invasive PD, used a laparoscopic-assisted PD (LAPD) approach and reported their case series, proposing the feasibility of LAPD^[69-74]. LAPD showed non-inferior results to open surgery in terms of perioperative and oncological outcomes (comparable number of harvested lymph nodes and higher R0 rates)^[75]. Similar results were also reported by Tan *et al.*^[76] and Mendoza *et al.*^[77], who showed no differences in oncological and perioperative outcomes between open PD and LAPD. Tian *et al.*^[68] reported a lower estimated blood loss and shorter time to first flatus and Wang *et al.*^[67] described again a lower intraoperative blood loss and a shorter LOS. Additionally, a lower rate of anastomosis related complications has been reported compared to totally laparoscopic PD performed by experienced pancreatic surgeons at the beginning of their learning curve^[78]. Similarly promising results were reported by Deichmann *et al.*^[79]. No differences in intraoperative characteristics and postoperative outcomes were found between LAPD and robotic-assisted PD by Piedimonte *et al.*^[80]. Patel *et al.*^[81] reported a shorter LOS and lower severe morbidity rate and reoperation rate in LAPD compared to TLS, although a progressive shift from LAPD to TLS was observed over time. Somewhat similar results were published by Wang *et al.*^[82], reporting an increased operative time and blood loss in LAPD relative to TLS but similar LOS, morbidity rate, and postoperative pancreatic fistula (POPF) rate, with LAPD adopted by more inexperienced surgeons. In addition, Goh *et al.*^[83] reported a more frequent adoption of the hybrid technique during their early experience to allow for a safer transition to totally MIS. van Hilst *et al.*^[84] compared postoperative outcomes in LAPD and TLS without finding any significant difference; similar results were reported by

Table 1. Hand-assisted laparoscopic distal pancreatectomy

	Period of enrollment	Surgical operation	Included approaches	N of HALS pancreatic procedures	HALS vs. open	HALS vs. TLS/robotic
Cuschieri ^[29] , 2000	-	DP, TP, minor pancreatic resections, liver resections,	HALS	2	-	-
Misawa et al. ^[53] , 2006	2004-2005	DP	HALS, open	8	Reduced IBL, LOS Similar OT	-
D'Angelica et al. ^[39] , 2006	2002-2004	DP	HALS	17	-	-
Pierce et al. ^[54] , 2007	2000-2006	DP, enucleation	HALS*, TLS	3	-	-
Teh et al. ^[55] , 2007	2002-2005	DP	HALS*, TLS, open	8	-	-
Tang et al. ^[56] , 2007	1999-2006	DP	HALS*, TLS, open ^o	2	-	-
Nakamura et al. ^[44] , 2008	2000-2007	DP	HALS*, TLS, open	5	-	-
Laxa et al. ^[57] , 2008	2002-2007	DP	HALS, TLS	7	-	-
Vijan et al. ^[58] , 2010	2004-2009	DP	HALS*, TLS, open	2	-	-
Jayaraman et al. ^[43] , 2010	2003-2009	DP	HALS*, TLS, open	38	-	-
Gumbs et al. ^[59] , 2012	-	DP	HALS*, TLS	4	-	-
Kneuert et al. ^[42] , 2012	2000-2011	DP	HALS, TLS	62	-	Increased LOS
Rostas et al. ^[60] , 2012	2008-2011	DP	HALS	34	-	-
Rutz et al. ^[61] , 2014	2009-2013	DP	HALS, TLS, open	21	-	Increased IBL, tumor size Similar LOS, morbidity
Postlewait et al. ^[41] , 2018	2000-2014	DP	HALS, TLS, robotic, open	46	Reduced IBL, LOS Similar specimen length, OT, and LN yield	Similar IBL, LOS
Gamboa et al. ^[16] , 2020	2010-2018	DP	HALS, TLS, robotic, open	109	Reduced IBL, LOS Similar OT, morbidity, LN yield, RO rate	-

The literature search was conducted on the PubMed database. The search terms used were "laparoscopy" OR "hand-assisted" AND "pancreatic resection" OR "distal pancreatectomy" OR "pancreatectomy" individually or in combination. A manual search of reference lists of included articles was conducted. Case reports were excluded from the table. N: Number; HALS: hand-assisted laparoscopic surgery; TLS: total laparoscopic surgery; DP: distal pancreatectomy; TP: total pancreatectomy; LOS: length of stay; IBL: intraoperative blood loss; OT: operative time; LN: lymph node. *HALS was not treated as a separate group from laparoscopy; ^ohistorical cohort.

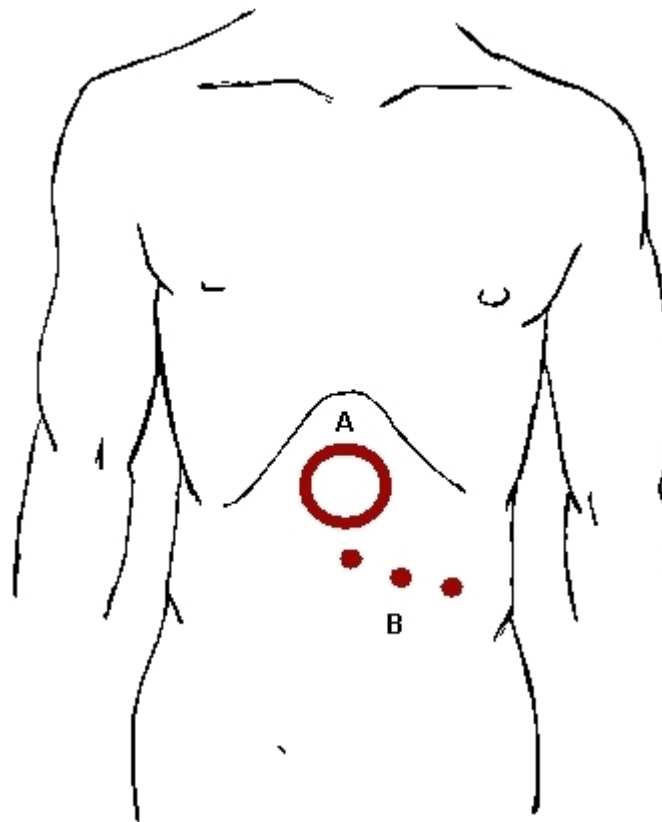


Figure 1. Trocars and hand-port placement in hand-assisted laparoscopic distal pancreatectomy. The placement of trocars widely changed among different reports. Proposed placement of trocars: (A) hand-port; and (B) ports for trocars placement.

Dulucq *et al.*^[85], Speicher *et al.*^[86] tracked the evolution of PD procedure over time at their institution, observing a progressive increase in the use of TLS over LAPD with growing experience and a parallel decrease of OT and complication rate; analogous findings were reported by Kim *et al.*^[87] and Lu *et al.*^[88]. The literature appears rather inhomogeneous, and it is difficult to draw definitive conclusions; however, in light of the reported data, the hybrid method appears to be safe and not inferior to the open approach^[69,70,89,90]. It also seems to provide some advantages over TLS in the early phase of the learning curve, but this may lose relevance in the case of surgeons with extensive experience in laparoscopy. A relevant piece of literature includes LAPD in the laparoscopic cases, and it is therefore difficult to extrapolate data on specific LAPD outcomes. The current available literature on the topic is summarized in Table 2; articles where the surgical technique is not specified were excluded. Placement of trocars and mini-laparotomy is shown in Figure 2.

MIS IN THE PANCREATIC SURGERY FIELD: WHERE ARE WE NOW?

Distal pancreatectomy

It is worth noting that, despite the initial setback, MIS has been greatly implemented in the pancreatic surgery field in recent years. Several observational studies, reviews, and metanalysis reported on the safety of minimally invasive distal pancreatectomy (MIDP) and proposed its advantages^[98-106]. A multicentric randomized controlled clinical trial comparing MIDP to open distal pancreatectomy demonstrated, despite a similar major complication rate, a reduced rate of delayed gastric emptying, a reduced intraoperative blood loss, a reduced time to functional recovery, and a better quality of life^[107]. In light of this evidence, MIDP has become the standard of care for benign and low malignant tumors^[108]. Regarding the use of

Table 2. Laparoscopic-assisted pancreaticoduodenectomy

	Period of enrollment	Surgical operation	Included approaches	N of LAS pancreatic procedures	LAS vs. open	LAS vs. TLS/robotic
Staudacher et al. ^[72] , 2005	2003-2004	PD	LAS	4	-	-
Dulucq et al. ^[85] , 2006	1999-2005	PD	LAS, TLS	9	-	Similar IBL, OT, LOS
Pugliese et al. ^[91] , 2008	2002-2006	PD	LAS*, TLS	7	-	-
Cho et al. ^[70] , 2009	2007-2008	PD	LAS	15	-	-
Machado et al. ^[92] , 2013	-	PD	LAS*, TLS	2	-	-
Kim et al. ^[87] , 2013	2007-2011	PD	LAS*, TLS	10	-	-
Lee et al. ^[73] , 2013	2009-2012	PD	LAS	42	-	-
Langan et al. ^[89] , 2014	2010-2013	PD	LAS, open	27	Reduced LOS Better QoL Similar OT, morbidity rate	-
Wang et al. ^[67] , 2014	2009-2013	PD	LAS, open	13	Decreased blood loss, LOS Similar complication and mortality rate	-
Wellner et al. ^[90] , 2014	1996-2013	PD	LAS, open	40	Decreased need for blood transfusions Similar complication and mortality rate	-
Speicher et al. ^[86] , 2014	2010-2013	PD	LAS, TLS, open	31	Increased IBL, POPF grade C rate Similar RO rate	Increased IBL, POPF grade C rate Similar RO rate
Liang et al. ^[93] , 2015	2011-2013	PD	LAS*, TLS, open	13	-	-
Piedimonte et al. ^[80] , 2015	2010-2014	PD	LAS, RA	14	-	Similar OT, IBL, morbidity rate
Wang et al. ^[54] , 2015	2010-2013	PD	LAS, TLS	6	-	Similar OT, IBL, morbidity
Mendoza et al. ^[77] , 2015	2014	PD	LAS, open	18	Reduced LOS Increased OT Similar IBL, LN yield, RO rate, morbidity rate, POPF rate	-
Liu et al. ^[71] , 2015	2011-2012	PD	LAS	21	-	-
Lu et al. ^[88] , 2016	2012-2015	PD	LAS*, TLS	9	-	-
Patel et al. ^[81] , 2017	2006-2016	PD	LAS, TLS	17	-	Reduced LOS, length of ICU stay, severe morbidity, reoperation rate
Kantor et al. ^[94] , 2018	2014-2015	PD	LAS*, TLS, robotic, open	304	-	-
Nassour et al. ^[95] , 2018	2014-2015	PD	LAS*, TLS, robotic, open	54	-	-
Deichmann et al. ^[79] , 2018	2000-2015	PD	LAS, open	60	Decreased OT, LOS, need for blood transfusions, CR-POPF rate	-

Kuesters <i>et al.</i> ^[75] , 2018	2010-2016	PD	LAS, open	62	Increased OT, RO rate Comparable lymph node yield, morbidity and mortality rate Shorter LOS	-
Tan <i>et al.</i> ^[76] , 2019	2014-2016	PD	LAS, open	20	Increased OT Similar morbidity rate, LN yield, RO rate Reduced time to deambulation	-
Goh <i>et al.</i> ^[83] , 2019	2014-2017	PD, TP	LAS*, TLS, robotic	18	-	-
van Hilst <i>et al.</i> ^[84] , 2019	2014-2018	PD	LAS, TLS	56	-	Increased conversion rate Similar IBL, OT, LOS, POPF rate, severe morbidity rate
Pham <i>et al.</i> ^[74] , 2020	2014-2019	PD	LAS	18	-	-
Tian <i>et al.</i> ^[68] , 2020	2013-2018	PD	LAS, open	36	Decreased blood loss Increased OT Similar CR-POPF rate, need for blood transfusions, LOS	-
Nieuwenhuijs <i>et al.</i> ^[78] , 2020	2016-2017	PD	LAS, open, TLS	10	Similar CR-POPF	-
Klompmaier <i>et al.</i> ^[96] , 2020	2012-2017	PD	LAS*, RA, TLS, open	130	-	-
Wang <i>et al.</i> ^[82] , 2020	2016-2018	PD	LAS, TLS	48	-	Increased OT, IBL Similar LOS, morbidity rate, POPF rate
Al-Sadairi <i>et al.</i> ^[69] , 2021	2019	PD	LAS	21	-	-

The literature search was conducted on the PubMed database; the search terms used were "laparoscopy" OR "laparoscopic-assisted" OR "hybrid" OR "hand-assisted" AND "pancreatic resection" OR "pancreaticoduodenectomy" OR "Whipple" or "pancreatectomy" individually or in combination. A manual search of reference lists of included articles was conducted. Case reports were excluded from the table. Articles with no full text available were excluded^[97]. Articles presenting new pancreatic anastomotic techniques were excluded. N: Number; LAS: laparoscopic-assisted surgery; TLS: total laparoscopic surgery; RA: robotic-assisted; PD: pancreaticoduodenectomy; TP: total pancreatectomy; LOS: length of stay; IBL: intraoperative blood loss; OT: operative time; QoL: quality of life; CR-POPF: clinically relevant postoperative pancreatic fistula. *LAS was not treated as a separate group from laparoscopy.

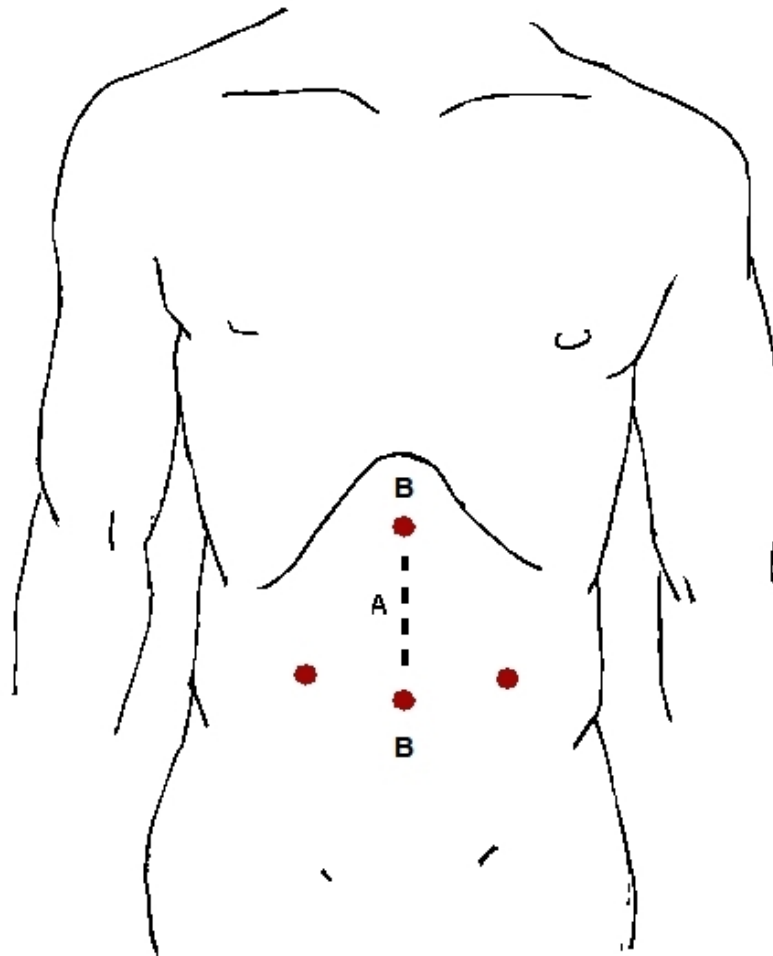


Figure 2. Trocars and mini-laparotomy placement in laparoscopic-assisted pancreaticoduodenectomy. The placement of trocars widely changed among different reports. Proposed placement of trocars: (A) mini-laparotomy; and (B) ports for trocars placement.

MIDP for the treatment of pancreatic ductal adenocarcinoma, available data suggest the oncological appropriateness of the procedure, but high-level evidence is still lacking. Oncological outcomes were comparable in terms of resection margins, disease free survival, and overall survival, while the number of harvested lymph nodes was found to be lower in one metanalysis and comparable in a second one^[101,109,110]. The DIPLOMA trial^[111] showed a higher R0 resection rate for MIDP, a less frequent Gerota's fascia resection, a lower number of harvested lymph nodes, and a comparable median survival. Randomized clinical trials are ongoing, trying to give a definitive answer. Regarding the choice of the type of MIS technique, several observational studies have been published comparing the robotic versus laparoscopic approach. Theoretically, the robotic platform should provide advantages in terms of improved dexterity and vision, allowing for completion of more complex procedures, but whether this translates into better outcomes and cost-effectiveness in clinical practice is still controversial^[112]. Reported outcomes in the literature are heterogeneous: recent metanalyses showed a higher rate of splenic vessel preservation and a lower conversion rate, but higher cost in Robotic DP compared to LDP^[113,114]. Another metanalysis reported a shorter LOS and an increase of spleen preservation rate at the expense of increased cost^[115]. Oncological and postoperative outcomes, such as POPF rate and overall morbidity, were comparable. Other studies showed no major differences in perioperative outcomes^[116-118]. Therefore, the Miami Guidelines conclude that both laparoscopic and robotic DP are considered valuable and equivalent options, and the choice

between the two depends on the preference of the surgeon and his familiarity with the technique^[108].

Pancreaticoduodenectomy

Pancreaticoduodenectomy is still performed in the majority of centers with an open approach due to its technical difficulty and the complex reconstructive phase. Available data on safety and feasibility of MIPD are conflicting. Reports from low-volume centers showed an increased morbidity and mortality after MIPD^[119,120], while experience in high-volume centers demonstrated a similar rate of mortality and morbidity compared to OPD. Moreover, in high-volume centers, LPD showed a lower rate of DGE, decreased blood loss, and a shorter hospital stay but a longer operative time^[36,121,122]. Three randomized clinical trials have been published with mixed results. Palanivelu *et al.*^[123] showed similar oncological and perioperative outcomes in OPD and LPD. Conversely, the LEOPARD-2 trial was interrupted early because of safety concerns due to a disproportionately high number of deaths in the LPD arm^[124], while the PADULAP trial reported a lower major complication rate and a shorter LOS and similar oncological outcomes^[125]. No major differences in outcomes have been reported between LPD and RPD^[126,127]. In view of existing evidence, the Miami Guidelines concluded that insufficient data exist to recommend MIPD over OPD. MIPD appears to be safe and feasible but only if performed by surgeons who have completed the learning curve and if set in high-volume centers experienced in both pancreatic surgery and MIS.

HALS: DOES IT STILL HAVE A ROLE IN PANCREATIC SURGERY PRACTICE TODAY?

Analysis of trends in the use of MIS in pancreatic surgery showed how, with time, we had a steep increase of MIDP, and the increase in number was paralleled by increasing complexity of procedures and a decrease in conversion rate and operative time^[42]. Moreover, the proportion of procedures performed with hand assistance decreased with time as surgeons became more skilled in MIS. It is worth noting that a recent analysis showed that MIDP is only used in one third of eligible patients^[128]. Therefore, on the one hand, HADP plays a very marginal role in high-volume centers, where surgeons have finished their learning curve, while, on the other hand, there are still centers in the process of implementation of MIS where HADP may play a fundamental role as a bridge to totally MIDP, easing the transition and shortening the learning curve. Moreover, HADP, with its shorter operative time, may be preferred in patients with multiple cardiological, pulmonary, and renal comorbidities who would not tolerate well the effects of prolonged anesthesia and pneumoperitoneum^[16]. Furthermore, HADP may be used as an intermediary step in conversion from MIDP to open in complex cases where manual assistance or tactile feedback is required or in the case of intraoperative complications because it appears that converted hand-assisted cases have a lower estimated blood loss and a shorter LOS than open^[16,30].

The role of MIS in PD is still not defined; MIPD can be performed in high-volume centers by experienced surgeons with acceptable outcomes, but the results are difficult to be generalized. In the process of the implementation of MIPD, LAPD may play a role as a bridge to totally laparoscopic PD allowing for a safer transition^[129,130].

In conclusion, the choice of the right approach needs to be tailored to the patient with a focus on his or her safety and to the surgeon keeping in mind his or her limits and expertise.

DECLARATIONS

Authors' contribution

Conception, design, drafting and revision of the manuscript: Donisi G, Zerbi A

Availability of data and materials

Not applicable.

Financial support and sponsorship

None.

Conflict of interest

Both authors declared that there are no conflicts of interest.

Ethical approval and consent to participate

Not applicable.

Consent for publication

Not applicable.

Copyright

© The Author(s) 2021.

REFERENCES

1. HIMAL HS. Minimally invasive (laparoscopic) surgery. *Surg Endosc* 2002;16:1647-52. DOI PubMed
2. Antoniou SA, Antoniou GA, Antoniou AI, Granderath FA. Past, present, and future of minimally invasive abdominal surgery. *JSLs* 2015;19:e2015. DOI PubMed PMC
3. Soper NJ, Brunt LM, Kerbl K. Laparoscopic general surgery. *N Engl J Med* 1994;330:409-19. DOI PubMed
4. Lewis A, Archer TJ. Laparoscopy in general surgery. *Br J Surg* 1981;68:778-80. DOI PubMed
5. Subramonian K, Muir G. The “learning curve” in surgery: what is it, how do we measure it and can we influence it? *BJU Int* 2004;93:1173-4. DOI PubMed
6. Zhu R, Cao Z, Qiu J, Zhang T. Minimally invasive pancreatic surgery: an upward spiral. *Laparoscopic, Endoscopic and Robotic Surgery* 2020;3:29-33. DOI
7. Esposito A, Balduzzi A, De Pastena M, et al. Minimally invasive surgery for pancreatic cancer. *Expert Rev Anticancer Ther* 2019;19:947-58. DOI PubMed
8. Bausch D, Keck T. Minimally invasive surgery of pancreatic cancer: feasibility and rationale. *Visc Med* 2018;34:440-3. DOI PubMed PMC
9. Sahakyan MA, Labori KJ, Primavesi F, Søreide K, Stättner S, Edwin B. Minimally invasive pancreatic surgery - where are we going? *Eur Surg* 2019;51:98-104. DOI
10. Nappo G, Perinel J, El Bechwaty M, Adham M. Minimally invasive pancreatic resection: is it really the future? *Dig Surg* 2016;33:284-9. DOI PubMed
11. Underwood PW, Gerber MH, Hughes SJ. Pitfalls of minimally invasive pancreatoduodenectomy. *Ann Pancreat Cancer* 2019;2:10.21037/apc.2018.12.02. DOI PubMed PMC
12. Gagner M, Pomp A. Laparoscopic pancreatic resection: Is it worthwhile? *J Gastrointest Surg* 1997;1:20-5; discussion 25. DOI PubMed
13. Targarona EM, Gracia E, Rodriguez M, et al. Hand-assisted laparoscopic surgery. *Arch Surg* 2003;138:133-41; discussion 141. DOI PubMed
14. Kavic MS. Hand-assisted laparoscopic surgery-HALS. *JSLs* 2001;5:101-3. PubMed PMC
15. Kavic MS. Hand-assisted laparoscopic surgery (HALS): a bridge to complex laparoscopic procedures. *JSLs* 2005;9:123-4. PubMed PMC
16. Gamboa AC, Aveson VG, Zaidi MY, et al. Lending a hand for laparoscopic distal pancreatectomy: the optimal approach? *HPB (Oxford)* 2020;22:690-701. DOI PubMed
17. animura S, Higashino M, Fukunaga Y, Osugi H. Hand-assisted laparoscopic distal gastrectomy with regional lymph node dissection for gastric cancer. *Surg Laparosc Endosc Percutan Tech* 2001;11:155-60. DOI
18. Okushiba S, Ohno K, Itoh K, et al. Hand-assisted endoscopic esophagectomy for esophageal cancer. *Surg Today* 2003;33:158-61. DOI PubMed
19. Fujiwara H, Shiozaki A, Konishi H, et al. Hand-assisted laparoscopic transhiatal esophagectomy with a systematic procedure for en bloc infracardinal lymph node dissection. *Dis Esophagus* 2016;29:131-8. DOI PubMed
20. DeMaria EJ, Schweitzer MA, Kellum JM, Meador J, Wolfe L, Sugerman HJ. Hand-assisted laparoscopic gastric bypass does not improve outcome and increases costs when compared to open gastric bypass for the surgical treatment of obesity. *Surg Endosc* 2002;16:1452-5. DOI PubMed
21. Gahagan JV, Garrett KA. Hand-assisted laparoscopic colon resection: review of literature and technique. *Ann Laparosc Endosc Surg*

- 2019;4:4-4. [DOI](#)
22. Ichihara T, Nagahata Y, Nomura H, et al. Laparoscopic lower anterior resection is equivalent to laparotomy for lower rectal cancer at the distal line of resection. *Am J Surg* 2000;179:97-8. [DOI](#) [PubMed](#)
23. Pietrabissa A, Moretto C, Carobbi A, Boggi U, Ghilli M, Mosca F. Hand-assisted laparoscopic low anterior resection: initial experience with a new procedure. *Surg Endosc* 2002;16:431-5. [DOI](#) [PubMed](#)
24. Tam MS, Kaoutzanis C, Mullard AJ, et al. A population-based study comparing laparoscopic and robotic outcomes in colorectal surgery. *Surg Endosc* 2016;30:455-63. [DOI](#) [PubMed](#)
25. Wolf JS Jr, Merion RM, Leichtman AB, et al. Randomized controlled trial of hand-assisted laparoscopic versus open surgical live donor nephrectomy. *Transplantation* 2001;72:284-90. [DOI](#) [PubMed](#)
26. Pietrabissa A, Boggi U, Moretto C, Ghilli M, Mosca F. Laparoscopic and hand-assisted laparoscopic live donor nephrectomy. *Semin Laparosc Surg* 2001;8:161-7. [PubMed](#)
27. Stifelman MD, Hull D, Sosa RE, et al. Hand assisted laparoscopic donor nephrectomy: a comparison with the open approach. *J Urol* 2001;166:444-8. [DOI](#) [PubMed](#)
28. Stifelman MD, Sosa RE, Shichman SJ. Hand-assisted laparoscopy in urology. *Rev Urol* 2001;3:63-71. [PubMed](#) [PMC](#)
29. Cuschieri A. Laparoscopic hand-assisted surgery for hepatic and pancreatic disease. *Surg Endosc* 2000;14:991-6. [DOI](#) [PubMed](#)
30. Gagner M, Gentileschi P. Hand-assisted laparoscopic pancreatic resection. *Semin Laparosc Surg* 2001;8:114-25. [PubMed](#)
31. Tada S, Iida T, Anazawa T, et al. Successful laparoscopic distal pancreatectomy for a large solid pseudopapillary neoplasm: a case report. *Asian J Endosc Surg* 2017;10:317-20. [DOI](#) [PubMed](#)
32. Shinci H, Takao S, Noma H, Mataka Y, Iino S, Aikou T. Hand-assisted laparoscopic distal pancreatectomy with minilaparotomy for distal pancreatic cystadenoma. *Surg Laparosc Endosc Percutan Tech* 2001;11:139-43. [PubMed](#)
33. Doi R, Ito D, Fujimoto K, et al. Hand-assisted laparoscopic resection of serous cystadenoma of the pancreas. *Surg Endosc* 2003;17:2028-31. [DOI](#) [PubMed](#)
34. Kaneko H, Takagi S, Joubara N, et al. Laparoscopy-assisted spleen-preserving distal pancreatectomy with conservation of the splenic artery and vein. *J Hepatobiliary Pancreat Surg* 2004;11:397-401. [DOI](#) [PubMed](#)
35. Klingler PJ, Hinder RA, Menke DM, Smith SL. Hand-assisted laparoscopic distal pancreatectomy for pancreatic cystadenoma. *Surg Laparosc Endosc* 1998;8:180-4. [PubMed](#)
36. Boggi U, Amorese G, Vistoli F, et al. Laparoscopic pancreaticoduodenectomy: a systematic literature review. *Surg Endosc* 2015;29:9-23. [DOI](#) [PubMed](#)
37. Cuschieri A, Jakimowicz JJ, van Spreuwel J. Laparoscopic distal 70% pancreatectomy and splenectomy for chronic pancreatitis. *Ann Surg* 1996;223:280-5. [DOI](#) [PubMed](#) [PMC](#)
38. Gagner M, Pomp A, Herrera MF. Early experience with laparoscopic resections of islet cell tumors. *Surgery* 1996;120:1051-4. [DOI](#) [PubMed](#)
39. D'Angelica M, Are C, Jarnagin W, et al. Initial experience with hand-assisted laparoscopic distal pancreatectomy. *Surg Endosc* 2006;20:142-8. [DOI](#) [PubMed](#)
40. Iacobone M, Citton M, Nitti D. Laparoscopic distal pancreatectomy: up-to-date and literature review. *World J Gastroenterol* 2012;18:5329-37. [DOI](#) [PubMed](#) [PMC](#)
41. Postlewait LM, Ethun CG, McInnis MR, et al. The hand-assisted laparoscopic approach to resection of pancreatic mucinous cystic neoplasms: an underused technique? *Am Surg* 2018;84:56-62. [PubMed](#)
42. Kneuert PJ, Patel SH, Chu CK, et al. Laparoscopic distal pancreatectomy: trends and lessons learned through an 11-year experience. *J Am Coll Surg* 2012;215:167-76. [DOI](#) [PubMed](#)
43. Jayaraman S, Gonen M, Brennan MF, et al. Laparoscopic distal pancreatectomy: evolution of a technique at a single institution. *J Am Coll Surg* 2010;211:503-9. [DOI](#) [PubMed](#)
44. Nakamura Y, Uchida E, Aimoto T, Matsumoto S, Yoshida H, Tajiri T. Clinical outcome of laparoscopic distal pancreatectomy. *J Hepatobiliary Pancreat Surg* 2009;16:35-41. [DOI](#) [PubMed](#)
45. Venkat R, Edil BH, Schulick RD, Lidor AO, Makary MA, Wolfgang CL. Laparoscopic distal pancreatectomy is associated with significantly less overall morbidity compared to the open technique: a systematic review and meta-analysis. *Ann Surg* 2012;255:1048-59. [DOI](#) [PubMed](#)
46. Kooby DA, Gillespie T, Bentrem D, et al. Left-sided pancreatectomy: a multicenter comparison of laparoscopic and open approaches. *Ann Surg* 2008;248:438-46. [DOI](#) [PubMed](#)
47. Patterson EJ, Gagner M, Salky B, et al. Laparoscopic pancreatic resection: single-institution experience of 19 patients. *J Am Coll Surg* 2001;193:281-7. [DOI](#)
48. Edwin B, Mala T, Mathisen Ø, et al. Laparoscopic resection of the pancreas: a feasibility study of the short-term outcome. *Surg Endosc* 2004;18:407-11. [DOI](#) [PubMed](#)
49. Lyu Y, Cheng Y, Wang B, Zhao S, Chen L. Comparison of 3 minimally invasive methods versus open distal pancreatectomy: a systematic review and network meta-analysis. *Surg Laparosc Endosc Percutan Tech* 2020;31:104-12. [DOI](#) [PubMed](#) [PMC](#)
50. Goh BKP, Lee SY, Kam JH, et al. Evolution of minimally invasive distal pancreatectomies at a single institution. *J Minim Access Surg* 2018;14:140-5. [DOI](#) [PubMed](#) [PMC](#)
51. Machado MA, Surjan RC, Goldman SM, Ardengh JC, Makdissi FF. Laparoscopic pancreatic resection. From enucleation to pancreatoduodenectomy. 11-year experience. *Arq Gastroenterol* 2013;50:214-8. [DOI](#) [PubMed](#)
52. Root J, Nguyen N, Jones B, et al. Laparoscopic distal pancreatic resection. *Am Surg* 2005;71:744-9. [PubMed](#)
53. Misawa T, Shiba H, Usuba T, et al. Systemic inflammatory response syndrome after hand-assisted laparoscopic distal

- pancreatectomy. *Surg Endosc* 2007;21:1446-9. DOI PubMed
54. Pierce RA, Spittler JA, Hawkins WG, et al. Outcomes analysis of laparoscopic resection of pancreatic neoplasms. *Surg Endosc* 2007;21:579-86. DOI PubMed
55. Teh SH, Tseng D, Sheppard BC. Laparoscopic and open distal pancreatic resection for benign pancreatic disease. *J Gastrointest Surg* 2007;11:1120-5. DOI PubMed
56. Tang CN, Tsui KK, Ha JP, Wong DC, Li MK. Laparoscopic distal pancreatectomy: a comparative study. *Hepatogastroenterology* 2007;54:265-71. PubMed
57. Laxa BU, Carbonell AM 2nd, Cobb WS, et al. Laparoscopic and hand-assisted distal pancreatectomy. *Am Surg* 2008;74:481-6; discussion 486. PubMed
58. Vijan SS, Ahmed KA, Harmsen WS, et al. Laparoscopic vs open distal pancreatectomy: a single-institution comparative study. *Arch Surg* 2010;145:616-21. DOI PubMed
59. Gumbs AA, Chouillard EK. Laparoscopic distal pancreatectomy and splenectomy for malignant tumors. *J Gastrointest Cancer* 2012;43:83-6. DOI PubMed
60. Rostas JW, Richards WO, Thompson LW. Improved rate of pancreatic fistula after distal pancreatectomy: parenchymal division with the use of saline-coupled radiofrequency ablation. *HPB (Oxford)* 2012;14:560-4. DOI PubMed PMC
61. Rutz DR, Squires MH, Maithe SK, et al. Cost comparison analysis of open versus laparoscopic distal pancreatectomy. *HPB (Oxford)* 2014;16:907-14. DOI PubMed PMC
62. Ammori BJ. Laparoscopic hand-assisted pancreaticoduodenectomy: initial UK experience. *Surg Endosc* 2004;18:717-8. DOI PubMed
63. Wang M, Zhang H, Wu Z, Zhang Z, Peng B. Laparoscopic pancreaticoduodenectomy: single-surgeon experience. *Surg Endosc* 2015;29:3783-94. DOI PubMed
64. Gumbs AA, Rodriguez Rivera AM, Milone L, Hoffman JP. Laparoscopic pancreatoduodenectomy: a review of 285 published cases. *Ann Surg Oncol* 2011;18:1335-41. DOI PubMed
65. Kimura Y, Hirata K, Mukaiya M, Mizuguchi T, Koito K, Katsuramaki T. Hand-assisted laparoscopic pylorus-preserving pancreaticoduodenectomy for pancreas head disease. *Am J Surg* 2005;189:734-7. DOI PubMed
66. Sánchez-Cabús S, Pittau G, Gelli M, Memeo R, Schwarz L, Sa Cunha A. Laparoscopic pancreaticoduodenectomy: hybrid surgical technique. *J Am Coll Surg* 2015;220:e7-11. DOI PubMed
67. Wang Y, Bergman S, Piedimonte S, Vanounou T. Bridging the gap between open and minimally invasive pancreaticoduodenectomy: the hybrid approach. *Can J Surg* 2014;57:263-70. DOI PubMed PMC
68. Tian F, Wang YZ, Hua SR, Liu QF, Guo JC. Laparoscopic assisted pancreaticoduodenectomy: an important link in the process of transition from open to total laparoscopic pancreaticoduodenectomy. *BMC Surg* 2020;20:89. DOI PubMed PMC
69. Al-Sadairi AR, Mimmo A, Rhaïem R, et al. Laparoscopic hybrid pancreaticoduodenectomy: initial single center experience. *Ann Hepatobiliary Pancreat Surg* 2021;25:102-11. DOI PubMed PMC
70. Cho A, Yamamoto H, Nagata M, et al. Comparison of laparoscopy-assisted and open pylorus-preserving pancreaticoduodenectomy for periampullary disease. *Am J Surg* 2009;198:445-9. DOI PubMed
71. Liu Z, Yu MC, Zhao R, et al. Laparoscopic pancreaticoduodenectomy via a reverse - "V" approach with four ports: initial experience and perioperative outcomes. *World J Gastroenterol* 2015;21:1588-94. DOI PubMed PMC
72. Staudacher C, Orsenigo E, Baccari P, Di Palo S, Crippa S. Laparoscopic assisted duodenopancreatectomy. *Surg Endosc* 2005;19:352-6. DOI PubMed
73. Lee JS, Han JH, Na GH, et al. Laparoscopic pancreaticoduodenectomy assisted by mini-laparotomy. *Surg Laparosc Endosc Percutan Tech* 2013;23:e98-102. DOI PubMed
74. Pham H, Nahm CB, Hollands M, et al. Hybrid laparoscopic pancreaticoduodenectomy: an Australian experience and a proposed process for implementation. *ANZ J Surg* 2020;90:1422-7. DOI PubMed
75. Kuesters S, Chikhladze S, Makowiec F, et al. Oncological outcome of laparoscopically assisted pancreatoduodenectomy for ductal adenocarcinoma in a retrospective cohort study. *Int J Surg* 2018;55:162-6. DOI PubMed
76. Tan JKH, Ng JJ, Yeo M, et al. Propensity score-matched analysis of early outcomes after laparoscopic-assisted versus open pancreaticoduodenectomy. *ANZ J Surg* 2019;89:E190-4. DOI PubMed
77. Mendoza AS 3rd, Han HS, Yoon YS, Cho JY, Choi Y. Laparoscopy-assisted pancreaticoduodenectomy as minimally invasive surgery for periampullary tumors: a comparison of short-term clinical outcomes of laparoscopy-assisted pancreaticoduodenectomy and open pancreaticoduodenectomy. *J Hepatobiliary Pancreat Sci* 2015;22:819-24. DOI PubMed
78. Nieuwenhuijs VB, de Klein GW, van Duijvendijk P, Patijn GA. Lessons learned from the introduction of laparoscopic pancreaticoduodenectomy. *J Laparoendosc Adv Surg Tech A* 2020;30:495-500. DOI PubMed
79. Deichmann S, Bolm LR, Honselmann KC, et al. Perioperative and long-term oncological results of minimally invasive pancreatoduodenectomy as hybrid technique - a matched pair analysis of 120 cases. *Zentralbl Chir* 2018;143:155-61. DOI PubMed PMC
80. Piedimonte S, Wang Y, Bergman S, Vanounou T. Early experience with robotic pancreatic surgery in a Canadian institution. *Can J Surg* 2015;58:394-401. DOI PubMed PMC
81. Patel B, Leung U, Lee J, Bryant R, O'Rourke N, Cavallucci D. Laparoscopic pancreaticoduodenectomy in Brisbane, Australia: an initial experience. *ANZ J Surg* 2018;88:E440-4. DOI PubMed
82. Wang C, Qi R, Li H, Shi X. Comparison of perioperative and oncological outcomes of hybrid and totally laparoscopic pancreatoduodenectomy. *Med Sci Monit* 2020;26:e924190. DOI PubMed PMC

83. Goh BKP, Low TY, Kam JH, Lee SY, Chan CY. Initial experience with laparoscopic and robotic surgery for the treatment of peripapillary tumours: single institution experience with the first 30 consecutive cases. *ANZ J Surg* 2019;89:E137-41. [DOI PubMed](#)
84. Hilst J, de Rooij T, van den Boezem PB, et al; Dutch Pancreatic Cancer Group. Laparoscopic pancreaticoduodenectomy with open or laparoscopic reconstruction during the learning curve: a multicenter propensity score matched study. *HPB (Oxford)* 2019;21:857-64. [DOI PubMed](#)
85. Dulucq JL, Wintringer P, Mahajna A. Laparoscopic pancreaticoduodenectomy for benign and malignant diseases. *Surg Endosc* 2006;20:1045-50. [DOI PubMed](#)
86. Speicher PJ, Nussbaum DP, White RR, et al. Defining the learning curve for team-based laparoscopic pancreaticoduodenectomy. *Ann Surg Oncol* 2014;21:4014-9. [DOI PubMed](#)
87. Kim SC, Song KB, Jung YS, et al. Short-term clinical outcomes for 100 consecutive cases of laparoscopic pylorus-preserving pancreaticoduodenectomy: improvement with surgical experience. *Surg Endosc* 2013;27:95-103. [DOI PubMed](#)
88. Lu C, Jin W, Mou YP, et al. Analysis of learning curve for laparoscopic pancreaticoduodenectomy. *J Vis Surg* 2016;2:145. [DOI PubMed PMC](#)
89. Langan RC, Graham JA, Chin AB, et al. Laparoscopic-assisted versus open pancreaticoduodenectomy: early favorable physical quality-of-life measures. *Surgery* 2014;156:379-84. [DOI PubMed](#)
90. Wellner UF, Küsters S, Sick O, et al. Hybrid laparoscopic versus open pylorus-preserving pancreaticoduodenectomy: retrospective matched case comparison in 80 patients. *Langenbecks Arch Surg* 2014;399:849-56. [DOI PubMed](#)
91. Pugliese R, Scandroglio I, Sansonna F, et al. Laparoscopic pancreaticoduodenectomy: a retrospective review of 19 cases. *Surg Laparosc Endosc Percutan Tech* 2008;18:13-8. [DOI PubMed](#)
92. Machado MA, Makdissi FF, Surjan RC, Machado MC. Laparoscopic pylorus-preserving pancreaticoduodenectomy with double jejunal loop reconstruction: an old trick for a new dog. *J Laparoendosc Adv Surg Tech A* 2013;23:146-9. [DOI PubMed](#)
93. Liang S, Jayaraman S. Getting started with minimally invasive pancreaticoduodenectomy: is it worth it? *J Laparoendosc Adv Surg Tech A* 2015;25:712-9. [DOI PubMed](#)
94. Kantor O, Pitt HA, Talamonti MS, et al. Minimally invasive pancreaticoduodenectomy: is the incidence of clinically relevant postoperative pancreatic fistula comparable to that after open pancreaticoduodenectomy? *Surgery* 2018;163:587-93. [DOI PubMed](#)
95. Nassour I, Wang SC, Christie A, et al. Minimally invasive versus open pancreaticoduodenectomy: a propensity-matched study from a national cohort of patients. *Ann Surg* 2018;268:151-7. [DOI PubMed](#)
96. Klompmaker S, van Hilst J, Wellner UF, et al; European consortium on Minimally Invasive Pancreatic Surgery (E-MIPS). Outcomes after minimally-invasive versus open pancreaticoduodenectomy: a pan-european propensity score matched study. *Ann Surg* 2020;271:356-63. [DOI PubMed](#)
97. Kuroki T, Adachi T, Okamoto T, Kanematsu T. A non-randomized comparative study of laparoscopy-assisted pancreaticoduodenectomy and open pancreaticoduodenectomy. *Hepatogastroenterology* 2012;59:570-3. [DOI PubMed](#)
98. Ohtsuka T, Nagakawa Y, Toyama H, et al. A multicenter prospective registration study on laparoscopic pancreaticectomy in Japan: report on the assessment of 1,429 patients. *J Hepatobiliary Pancreat Sci* 2020;27:47-55. [DOI PubMed](#)
99. Jusoh AC, Ammori BJ. Laparoscopic versus open distal pancreatectomy: a systematic review of comparative studies. *Surg Endosc* 2012;26:904-13. [DOI PubMed](#)
100. Mehrabi A, Hafezi M, Arvin J, et al. A systematic review and meta-analysis of laparoscopic versus open distal pancreatectomy for benign and malignant lesions of the pancreas: it's time to randomize. *Surgery* 2015;157:45-55. [DOI PubMed](#)
101. Nakamura M, Nakashima H. Laparoscopic distal pancreatectomy and pancreaticoduodenectomy: is it worthwhile? *J Hepatobiliary Pancreat Sci* 2013;20:421-8. [DOI PubMed](#)
102. Nigri GR, Rosman AS, Petrucciani N, et al. Metaanalysis of trials comparing minimally invasive and open distal pancreatectomies. *Surg Endosc* 2011;25:1642-51. [DOI PubMed](#)
103. Ricci C, Casadei R, Taffurelli G, et al. Laparoscopic versus open distal pancreatectomy for ductal adenocarcinoma: a systematic review and meta-analysis. *J Gastrointest Surg* 2015;19:770-81. [DOI PubMed](#)
104. Pericleous S, Middleton N, McKay SC, Bowers KA, Hutchins RR. Systematic review and meta-analysis of case-matched studies comparing open and laparoscopic distal pancreatectomy: is it a safe procedure? *Pancreas* 2012;41:993-1000. [DOI PubMed](#)
105. Xie K, Zhu YP, Xu XW, Chen K, Yan JF, Mou YP. Laparoscopic distal pancreatectomy is as safe and feasible as open procedure: a meta-analysis. *World J Gastroenterol* 2012;18:1959-67. [DOI PubMed PMC](#)
106. Braga M, Pecorelli N, Ferrari D, Balzano G, Zuliani W, Castoldi R. Results of 100 consecutive laparoscopic distal pancreatectomies: postoperative outcome, cost-benefit analysis, and quality of life assessment. *Surg Endosc* 2015;29:1871-8. [DOI PubMed](#)
107. Rooij T, van Hilst J, van Santvoort H, et al; Dutch pancreatic cancer group. minimally invasive versus open distal pancreatectomy (LEOPARD): a multicenter patient-blinded randomized controlled trial. *Ann Surg* 2019;269:2-9. [DOI PubMed](#)
108. Asbun HJ, Moekotte AL, Vissers FL, et al; International Study Group on Minimally Invasive Pancreas Surgery (I-MIPS). The miami international evidence-based guidelines on minimally invasive pancreas resection. *Ann Surg* 2020;271:1-14. [DOI PubMed](#)
109. Hilst J, Korrel M, de Rooij T, et al; DIPLOMA study group. Oncologic outcomes of minimally invasive versus open distal pancreatectomy for pancreatic ductal adenocarcinoma: a systematic review and meta-analysis. *Eur J Surg Oncol* 2019;45:719-27. [DOI PubMed](#)
110. Riviere D, Gurusamy KS, Kooby DA, et al. Laparoscopic versus open distal pancreatectomy for pancreatic cancer. *Cochrane Database Syst Rev* 2016;4:CD011391. [DOI PubMed PMC](#)
111. Hilst J, de Rooij T, Klompmaker S, et al; European Consortium on Minimally Invasive Pancreatic Surgery (E-MIPS). Minimally invasive versus open distal pancreatectomy for ductal adenocarcinoma (DIPLOMA): a pan-European propensity score matched study.

- Ann Surg* 2019;269:10-7. DOI PubMed
112. Lefor AK. Robotic and laparoscopic surgery of the pancreas: an historical review. *BMC Biomed Eng* 2019;1:2. DOI PubMed PMC
113. Xu SB, Jia CK, Wang JR, Zhang RC, Mou YP. Do patients benefit more from robot assisted approach than conventional laparoscopic distal pancreatectomy? *J Formos Med Assoc* 2019;118:268-78. DOI PubMed
114. Xourafas D, Ashley SW, Clancy TE. Comparison of perioperative outcomes between open, laparoscopic, and robotic distal pancreatectomy: an analysis of 1815 patients from the ACS-NSQIP procedure-targeted pancreatectomy database. *J Gastrointest Surg* 2017;21:1442-52. DOI PubMed
115. Niu X, Yu B, Yao L, et al. Comparison of surgical outcomes of robot-assisted laparoscopic distal pancreatectomy versus laparoscopic and open resections: A systematic review and meta-analysis. *Asian J Surg* 2019;42:32-45. DOI PubMed
116. Huang B, Feng L, Zhao J. Systematic review and meta-analysis of robotic versus laparoscopic distal pancreatectomy for benign and malignant pancreatic lesions. *Surg Endosc* 2016;30:4078-85. DOI PubMed
117. Gavrilidis P, Lim C, Menahem B, Lahat E, Salloum C, Azoulay D. Robotic versus laparoscopic distal pancreatectomy - the first meta-analysis. *HPB (Oxford)* 2016;18:567-74. DOI PubMed PMC
118. Lyman WB, Passeri M, Sastry A, et al. Robotic-assisted versus laparoscopic left pancreatectomy at a high-volume, minimally invasive center. *Surg Endosc* 2019;33:2991-3000. DOI PubMed
119. Adam MA, Choudhury K, Dinan MA, et al. Minimally invasive versus open pancreaticoduodenectomy for cancer: practice patterns and short-term outcomes among 7061 patients. *Ann Surg* 2015;262:372-7. DOI PubMed
120. Dokmak S, Ftériche FS, Aussilhou B, et al. Laparoscopic pancreaticoduodenectomy should not be routine for resection of periampullary tumors. *J Am Coll Surg* 2015;220:831-8. DOI PubMed
121. Sharpe SM, Talamonti MS, Wang CE, et al. Early national experience with laparoscopic pancreaticoduodenectomy for ductal adenocarcinoma: a comparison of laparoscopic pancreaticoduodenectomy and open pancreaticoduodenectomy from the national cancer data base. *J Am Coll Surg* 2015;221:175-84. DOI PubMed
122. Lai EC, Tang CN. Current status of robot-assisted laparoscopic pancreaticoduodenectomy and distal pancreatectomy: a comprehensive review. *Asian J Endosc Surg* 2013;6:158-64. DOI PubMed
123. Palanivelu C, Senthilnathan P, Sabnis SC, et al. Randomized clinical trial of laparoscopic versus open pancreatoduodenectomy for periampullary tumours. *Br J Surg* 2017;104:1443-50. DOI PubMed
124. van Hilst J, de Rooij T, Bosscha K, et al. Laparoscopic versus open pancreatoduodenectomy for pancreatic or periampullary tumours (LEOPARD-2): a multicentre, patient-blinded, randomised controlled phase 2/3 trial. *Lancet Gastroenterol Hepatol* 2019;4:199-207. DOI PubMed
125. Poves I, Burdío F, Morató O, et al. Comparison of perioperative outcomes between laparoscopic and open approach for pancreatoduodenectomy: the PADULAP randomized controlled trial. *Ann Surg* 2018;268:731-9. DOI PubMed
126. Nassour I, Wang SC, Porembka MR, et al. Robotic versus laparoscopic pancreaticoduodenectomy: a NSQIP analysis. *J Gastrointest Surg* 2017;21:1784-92. DOI PubMed PMC
127. Jiang DJ, Hogg ME. Robotic pancreaticoduodenectomy versus laparoscopic pancreaticoduodenectomy. *Laparosc Surg* 2021;5:22-22. DOI
128. Konstantinidis IT, Lewis A, Lee B, et al. Minimally invasive distal pancreatectomy: greatest benefit for the frail. *Surg Endosc* 2017;31:5234-40. DOI PubMed PMC
129. Rooij T, Klompmaker S, Abu Hilal M, Kendrick ML, Busch OR, Besselink MG. Laparoscopic pancreatic surgery for benign and malignant disease. *Nat Rev Gastroenterol Hepatol* 2016;13:227-38. DOI PubMed
130. Kamarajah SK, Bundred JR, Marc OS, et al. A systematic review and network meta-analysis of different surgical approaches for pancreaticoduodenectomy. *HPB (Oxford)* 2020;22:329-39. DOI PubMed